Ectopic Ossification of the Triceps Muscle After Application of Bone Morphogenetic Protein-7 to the Distal Humerus for Recalcitrant Nonunion: A Case Report

Robert W. Wysocki, MD, Mark S. Cohen, MD

From the Department of Orthopaedic Surgery, Rush Medical College, Chicago, IL.

We report a case of triceps muscle ectopic ossification and resultant elbow stiffness after application of recombinant human bone morphogenetic protein to a distal humerus nonunion site. We recommend caution when using this product in the upper extremity in regions where there is close approximation of soft tissue to bone and where loss of motion would be problematic. (J Hand Surg 2007;32A:647–650. Copyright © 2007 by the American Society for Surgery of the Hand.)

Key words: BMP-7, bone morphogenetic proteins, ectopic or heterotopic ossification, nonunion, OP-1.

Despite advances in fracture fixation and treatment, impaired healing occurs in 5% to 10% of fractures[1] including 2% to 10% of distal humerus fractures.[2,3] The first line of treatment for established atrophic nonunions is autogenous bone graft.[4] This provides only a limited quantity of bone graft and carries with it the risk of a second surgery, as well as short- and long-term donor site morbidity.[5–7]

In the case of recalcitrant atrophic nonunion in which autogenous bone grafting has failed or is not feasible, research has focused on osteoinductive materials such as the bone morphogenetic proteins (BMPs) to provide further biologic stimulus for healing. Recombinant human bone morphogenetic protein-7 (rhBMP-7), or osteogenic protein-1 (OP-1), is a member of the osteogenic protein subclass of the BMPs, and clinical studies[8,9] have shown it to be a safe and effective adjunct in promoting the healing of recalcitrant nonunions and open fractures. This report describes a complication related to the use of BMP in the treatment of a distal humeral nonunion.

Case Report

A 29-year-old, right-hand–dominant man fell from a height sustaining an intra-articular, comminuted, bicolumnar fracture of the left distal humerus. Forty-eight hours after the injury, the patient was taken to the operating room at an outside facility, where an open reduction and internal fixation was performed through an olecranon osteotomy. Medial and lateral plates were applied without complication.

The patient was referred to our institution 5 months after surgery because of continued left elbow pain and stiffness since surgery. Physical examination showed a loss of 35° of extension and 20° of flexion compared with the uninjured side. Radiographs and a computed tomography scan showed a delayed union extending down through the initial trochlear injury.

The patient was taken to the operating room 6 months after the initial procedure for revision open reduction and internal fixation. Through a triceps-sparing approach, a fibrous nonunion of both the medial and lateral humeral columns was identified with loosening of the hardware. A revision of both the medial and lateral plates was performed with longer implants and locking screw technology. Autogenous left iliac crest bone graft was applied to supplement healing. A formal elbow release of the anterior and posterior capsules was also performed in an effort to decrease stress on the fixation after surgery.

Five months after revision surgery, the patient was asymptomatic and had regained a range of elbow motion from 10° to 130°. Despite the lack of symp-

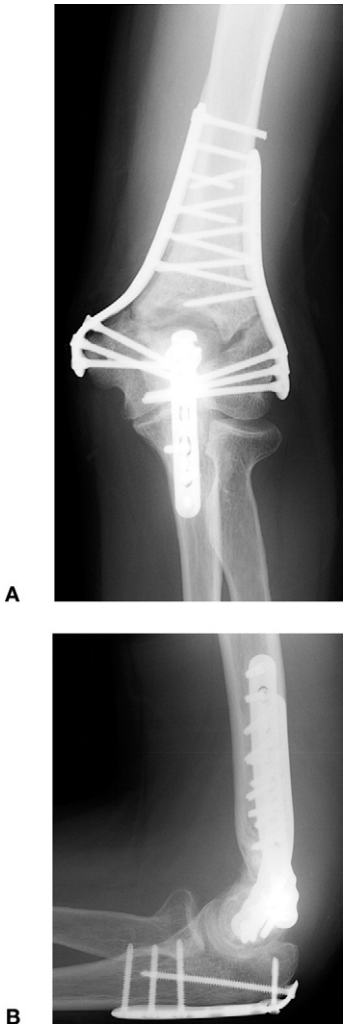

Figure 1. (A) Anteroposterior and (B) lateral radiographs 6 months after revision surgery. Note the continued nonunion lines in the lateral and medial humeral columns and the lack of any ectopic ossification.

toms, he continued to have radiographic evidence of a delayed union of both columns (Fig. 1). This was confirmed on computed tomography. The patient now admitted to a history of smoking.

Six months after his revision surgery and 1 year from the initial trauma, the patient had repeat bone grafting of both columns of the distal humerus. Through a limited incision, the triceps was elevated laterally and split medially over the humeral columns to expose the nonunion sites. As planned, a bone dowel saw (Precision Bone Grafting System; Kaltec Pty Ltd., Edwardstown, SA, Australia) was used to resect 11-mm–diameter bicortical plugs from the distal humeral columns. Care was taken to center the plugs on the nonunion sites. The resected plugs were sent for pathologic and microbiologic study, and no evidence of infection was identified. Slightly larger 12-mm bicortical bone dowel plugs were removed from the right anterior iliac crest, along with additional cancellous autograft. As decided in the preoperative plan, a single dose of 3.5 mg of recombinant human OP-1 was mixed with bovine type I collagen carrier and normal saline to make 5 mL of OP-1 putty (OP-1 Implant; Stryker Biotech, Hopkinton, MA). The 2 iliac crest dowels were coated with putty and gently impacted into the nonunion sites. Because the iliac crest dowels were shorter than the anteroposterior diameter of the humerus, these were countersunk slightly beneath the posterior cortex. The remainder of the OP-1 putty was mixed with the cancellous autograft and packed on top of the dowels to fill the remainder of the cavity. Care was taken to ensure that no bone graft extruded into the soft tissues. The wound was then irrigated, the tourniquet was deflated, meticulous hemostasis was obtained, and the wound was closed in the usual fashion. After surgery, the patient's upper extremity was placed in a hanging arm sling overnight, and he was discharged home the morning after surgery.

The initial postoperative course was unremarkable. Radiographs showed appropriate position of the dowels in the columns, and the patient was started on an early rehabilitation program. He subsequently developed progressive elbow stiffness, however, that was resistant to formal therapy including patient-adjusted static bracing. At 10 weeks after surgery, his elbow range of motion had decreased from 10° to 120° at 2 weeks to 45° to 100° at 5 and 10 weeks. He denied any smoking over the 10 weeks after his revision with OP-1. Radiographs showed profound heterotopic ossification posteriorly within the triceps muscle (Fig. 2). The patient refused further treatment.

Discussion

The BMPs are members of the transforming growth factor-beta superfamily, which have been shown to induce bone formation and maturation through a series of cellular events, including mesenchymal cell infiltration, cartilage formation, vascularization, bone formation and remodeling, and lastly population of the newly formed bone by hematopoietic bone marrow elements.[10–12] Early clinical series have shown OP-1 to be effective and safe in promoting union in open fractures and long bone nonunions,[8,9] spinal fusion,[13–15] and femoral implant ingrowth[16] and strut allograft healing in total hip arthroplasty.[17]

Several of the early basic science studies on OP-1 showed the ability of OP-1 to stimulate endochondral

Figure 2. Lateral radiograph taken 10 weeks after surgery shows ectopic ossification posterior to the elbow within the triceps muscle.

bone formation in ectopic extraskeletal sites. Ripamonti et al,[18,19] using OP-1 combined with a collagen carrier, stimulated endochondral bone formation in primate rectus abdominis muscle. Zhang et al[20] found that OP-1 injected directly into a pouch within the adductor musculature of rats was similarly able to induce bone formation. Lastly, Forslund and Aspenberg[21] found that OP-1 injected percutaneously into the rabbit Achilles tendon could stimulate bone formation.

Despite the potential for OP-1 to induce ectopic bone in animal models, this complication has not been identified in early clinical series. Dimitriou et al[8] treated 27 consecutive long bone nonunions with OP-1, including 3 humeral nonunions, and achieved a 92% union rate with no reported ectopic ossification. Friedlaender[9] et al, in a prospective, randomized trial comparing OP-1 with autogenous iliac crest bone graft in 124 tibial nonunions, found no significant difference between union rates in the 2 groups and no cases of ectopic ossification. McKee et al reported a union rate of 89% in long bone nonunions, including 11 humeri, with OP-1 with no cases of ectopic ossification (McKee MD et al, presented at the 71st Annual Meeting of the American Academy of Orthopaedic Surgeons, 2004). An additional series by McKee examined the outcome of open tibial fractures treated with intramedullary nailing, where 1 group had OP-1 placed at the fracture site at the time of definitive wound closure and 1 group did not. There were no cases of ectopic ossification in the OP-1 group (McKee MD, presented at the 18th Annual Meeting of the Orthopaedic Trauma Association, 2002). Similarly, studies[13,15] of OP-1 when used as an adjunct in posterior spinal fusion have reported no cases of ectopic bone as a complication.

Several investigators have specifically studied the safety profile of OP-1 when placed in close approximation to soft tissues. Paramore et al[22] applied OP-1 to the subarachnoid space and a fusion bed in a canine model. All animals treated with OP-1 developed mild spinal stenosis from new bone formation in the subarachnoid space that compressed the spinal cord. Poynton and Lane[23] emphasized the importance of keeping the BMP in the fusion bed and away from spinal decompression sites to avoid the possibility of bone formation, which could compress neural structures. These researchers also advised both avoiding irrigation and maintaining meticulous hemostasis after placement of the BMP, because either irrigation or hematoma can cause BMP to extrude from the intended site.

Our report describes a complication of massive ectopic ossification within the triceps directly adjacent to an area where OP-1 was used, leading to marked loss of elbow motion. We believe that this complication was directly related to the use of OP-1. This is supported by the pattern and extent of the ectopic bone that formed in this case. Although ectopic bone is not unusual about the elbow, when it occurs posteriorly it is typically located beneath and not within the muscle fibers of the triceps.[24,25]

In our patient, after the dowels were seated, the OP-1 was mixed with pure cancellous bone and packed posteriorly into the defects in the medial and lateral columns. After surgery, we surmise that the hanging position of the patient's upper extremity overnight may have promoted leakage of the OP-1 directly into the triceps, which was split medially. It is also possible that the use of irrigation after OP-1 placement could have caused leakage of material and predisposed the patient to this complication.[23] Nonetheless, the extent and location of the ectopic bone formation in this clinical setting is highly atypical and suggests some contribution from the OP-1. This

is especially true given the ability of the drug to specifically form extraosseous bone when placed within skeletal muscle.[18,19]

We recommend that OP-1 be used with caution in the upper extremity where formation of excess bone could potentially restrict motion, such as in periarticular areas of the elbow or wrist. As recommended by previous researchers,[22,23] one must maintain meticulous hemostasis, limit the exposure only to what is necessary, avoid irrigation after placement of the BMP, and avoid placement of the material directly adjacent to neurovascular structures where compression from excess bone formation could be problematic.

Received for publication January 9, 2007; accepted in revised form March 2, 2007.

No benefits in any form have been received or will be received from a commercial party related directly or indirectly to the subject of this article.

Corresponding author: Robert W. Wysocki, MD, 1150 W Lill Avenue, Apt #3, Chicago, IL 60614; e-mail: Robert_Wysocki@rsh.net.

Copyright © 2007 by the American Society for Surgery of the Hand

0363-5023/07/32A05-0010$32.00/0
doi:10.1016/j.jhsa.2007.03.001

References

1. Praemer A, Furner S, Rice DP. Musculoskeletal Injuries. In: ed. Musculoskeletal conditions in the United States. Park Ridge: American Academy of Orthopaedic Surgeons, 1992: 85–124.
2. Helfet DL, Schmeling GJ. Bicondylar intraarticular fractures of the distal humerus in adults. Clin Orthop 1993;292:26–36.
3. Pugh DM, McKee MD. Advances in the management of humeral nonunion. J Am Acad Orthop Surg 2003;11:48–59.
4. Canalis E. The hormonal and local regulation of bone formation. Endocr Rev 1983;4:62–77.
5. Arrington ED, Smith WJ, Chambers HG, Bucknell AL, Davino NA. Complications of iliac crest bone graft harvesting. Clin Orthop 1996;329:300–309.
6. Fernyhough JC, Schimandle JJ, Weigel MC, Edwards CC, Levine AM. Chronic donor site pain complicating bone graft harvesting from the posterior iliac crest for spinal fusion. Spine 1992;17:1474–1480.
7. Younger EM, Chapman MW. Morbidity at bone graft donor sites. J Orthop Trauma 1989;3:192–195.
8. Dimitriou R, Dahabreh Z, Katsoulis E, Matthews SJ, Branfoot T, Giannoudis PV. Application of recombinant BMP-7 on persistent upper and lower limb non-unions. Injury 2005; 36(Suppl 4):S51–59.
9. Friedlaender GE, Perry CR, Cole JD, Cook SD, Cierny G, Muschler GF, et al. Osteogenic protein-1 (bone morphogenetic protein-7) in the treatment of tibial nonunions. J Bone Joint Surg 2001;83A(Suppl 1):S151–158.
10. Reddi AH. Cell biology and biochemistry of endochondral bone development. Coll Relat Res 1981;1:209–226.
11. Sampath TK, Coughlin JE, Whetstone RM, Banach D, Corbett C, Ridge RJ, et al. Bovine osteogenic protein is composed of dimers of OP-1 and BMP-2A, two members of the transforming growth factor-beta superfamily. J Biol Chem 1990;265:13198–13205.
12. Wozney JM. Overview of bone morphogenetic proteins. Spine 2002;27:S2–S8.
13. Cook SD, Dalton JE, Tan EH, Whitecloud TS III, Rueger DC. *In vivo* evaluation of recombinant human osteogenic protein (rhOP-1) implants as a bone graft substitute for spinal fusions. Spine 1994;19:1655–1663.
14. Grauer JN, Patel TC, Erulkar JS, Troiano NW, Panjabi MM, Friedlaender GE. 2000 Young Investigator Research Award winner. Evaluation of OP-1 as a graft substitute for intertransverse process lumbar fusion. Spine 2001;26:127–133.
15. Vaccaro AR, Anderson DG, Patel T, Fischgrund J, Truumees E, Herkowitz HN, et al. Comparison of OP-1 Putty (rhBMP-7) to iliac crest autograft for posterolateral lumbar arthrodesis: a minimum 2-year follow-up pilot study. Spine 2005;30:2709–2716.
16. Cook SD, Barrack RL, Santman M, Patron LP, Salkeld SL, Whitecloud TS III. The Otto Aufranc Award. Strut allograft healing to the femur with recombinant human osteogenic protein-1. Clin Orthop 2000;381:47–57.
17. Zhang R, An Y, Toth CA, Draughn RA, Dimaano NM, Hawkins MV. Osteogenic protein-1 enhances osseointegration of titanium implants coated with peri-apatite in rabbit femoral defect. J Biomed Mater Res B Appl Biomater 2004; 71:408–413.
18. Ripamonti U, Ramoshebi LN, Matsaba T, Tasker J, Crooks J, Teare J. Bone induction by BMPs/OPs and related family members in primates. J Bone Joint Surg 2001;83A(Suppl 1):S116–S127.
19. Ripamonti U, Crooks J, Rueger DC. Induction of bone formation by recombinant human osteogenic protein-1 and sintered porous hydroxyapatite in adult primates. Plast Reconstr Surg 2001;107:977–988.
20. Zhang R, Xu D, Landeryou T, Toth C, Dimaano N, Berry J, et al. Ectopic bone formation using osteogenic protein-1 carried by a solution precipitated hydroxyapatite. J Biomed Mater Res A 2004;71:412–418.
21. Forslund C, Aspenberg P. OP-1 has more effect than mechanical signals in the control of tissue differentiation in healing rat tendons. Acta Orthop Scand 1998;69:622–626.
22. Paramore CG, Lauryssen C, Rauzzino MJ, Wadlington VR, Palmer CA, Brix A, et al. The safety of OP-1 for lumbar fusion with decompression—a canine study. Neurosurgery 1999;44:1151–1155.
23. Poynton AR, Lane JM. Safety profile for the clinical use of bone morphogenetic proteins in the spine. Spine 2002;27: S40–S48.
24. Cohen MS. Heterotopic ossification of the elbow. In: Jupiter JB, ed. The stiff elbow. Rosemont: American Academy of Orthopaedic Surgeons, 2006:31–40.
25. Jupiter JB, O'Driscoll SW, Cohen MS. The assessment and management of the stiff elbow. Instr Course Lect 2003;52: 93–111.